Unusual conditions

AUTHOR
Dr Nigel Stollery
MB BS DPD
GP, Kibworth, Leicestershire and clinical assistant in dermatology, Leicester Royal Infirmary

Pyoderma gangrenosum



This is a rare ulcerating cutaneous condition of unknown aetiology which was first described in 1930. It affects approximately 1 in 100,000 people and is associated with systemic disease in 50% of cases (e.g. inflammatory bowel disease, hepatitis, lupus and arthritis). At first, there is usually a small painful lesion that patients frequently assume to be a bite. As the condition develops pain is the main problem and strong analgesia is usually required.

There is no single effective treatment that suits all cases. If the patient has an underlying disease then getting this under control will help.

Topical treatments include steroids, tacrolimus and appropriate dressings. Oral therapies such as steroids, ciclosporin, azathioprine and dapsone may also be effective. Other treatment options include hyperbaric oxygen, iv pulsed methylprednisolone and infliximab.

Subacromial bursitis

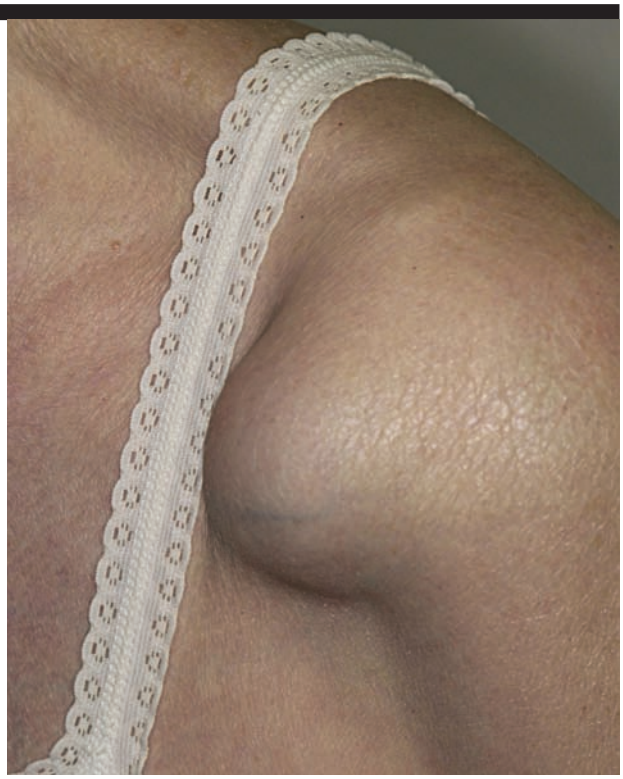

Subacromial bursitis is caused by inflammation of the bursa that separates the superior surface of the supraspinatus tendon from the overlying coraco-acromial ligament, acromion, coracoid and the deep surface of the deltoid muscle.

Primary inflammation of this bursa is rare and may be associated with autoimmune inflammatory conditions such as rheumatoid arthritis, Reiter's syndrome, gout, pseudogout and infection. Treatment approaches include rest, NSAIDs, steroid injections and physiotherapy.

Juvenile plantar dermatosis



Also referred to as 'sweaty sock syndrome' this condition affects the plantar aspect of the feet of children between the ages of 3 and 14. It is rarely seen after puberty. Juvenile plantar dermatosis occurs more often in boys than girls and is worse in the summer months. Affected feet have a shiny, glazed appearance with painful fissures and scaling. The weightbearing areas of the feet are usually most affected whereas the heel and toe webs tend to be unscathed. As the condition is thought to be associated with sweating, management includes keeping the feet cool and dry, not wearing trainers, regular application of greasy emollients and, if there is significant inflammation present, topical steroids. It is often treated, in error, as a fungal infection and there is no proven benefit from the use of topical antifungals.

Lipoma



Lipomas can be found anywhere on the body. They are usually asymptomatic and small. Currently many PCTs restrict treatment on the NHS unless the lesions are greater than a certain size. In my area it is around 2 cm in diameter. Sometimes lipomas can become much larger than this and cause problems because of their bulk. This one was unusual in that it was so large that the patient found it uncomfortable to sit down or lie on her right side. When excision is undertaken patients need to be informed that recurrence is common.

»

Submandibular stone

Gallstones and renal stones are relatively common and most patients are aware of their existence. Less common are stones forming in the salivary glands. One theory suggests these may develop as a result of toothpaste entering the duct around which the stone develops. As a result of the stone formation the duct can become occluded leading to acute swelling when the gland is stimulated. Patients typically describe swelling and discomfort after eating sour or spicy food which then gradually decreases as the trapped saliva drains. Sometimes the stone is passed spontaneously, in other cases surgical intervention may be required.



Maggot infestation

The importance of a thorough examination can never be underestimated as this case demonstrates. This lady presented with pain between her fourth and fifth toes. She had a long history of arthritis and thought the pain may have been associated with this. Her mobility was poor and she hadn't been able to check the toes herself. Her husband had tried to have a look and had noticed a small amount of bleeding coming from between the toes.
On initial inspection there was no obvious swelling, redness or bleeding. When the toes were parted, the cause was clearly seen - a small cluster of maggots. They were easily removed and the pain settled.

